

ALLOGRAFT TYMPANOPLASTY TYPE 1 IN THE CHILDHOOD POPULATION

EVERT P. P. M. HAMANS, MD
THOMAS SOMERS, MD

PAUL J. GOVAERTS, MD, MS
F. ERWIN OFFECIERS, MD, PHD

ANTWERP-WILRIJK, BELGIUM

Seventy allograft type 1 tympanoplasties in children under 16 years of age were studied retrospectively. Only patients with a tympanic membrane perforation without cholesteatoma and a normal ossicular chain were included. Short-term and long-term anatomic and functional results were analyzed after a mean follow-up of 40 months. The overall short-term take rate was 97% and the long-term take rate was 88%. A number of variables with alleged prognostic value for surgical outcome were analyzed, but none showed statistical correlation with either anatomic or functional results. A median hearing gain of 10 dB was achieved, which was stable over time. We conclude that allograft tympanoplasty type 1 in this group of children is anatomically and functionally successful regardless of age.

KEY WORDS — allograft tympanoplasty, child, chronic otitis media, homograft tympanoplasty.

INTRODUCTION

A surgical treatment of chronic or recurrent otitis media without cholesteatoma, type 1 tympanoplasty¹ in children has always been controversial. The controversy concerning the timing of surgery is mainly based on valid arguments from both the literature and the experience of many surgeons. Immature aeration of the middle ear, recurrent upper respiratory tract infections, and a difficult surgical anatomy have a negative influence on surgical outcome.^{2,3} On the other hand, early restoration of auditory function and prevention of further progression of middle ear disease (and possibly progression to cholesteatoma) caused by recurrent otorrhea are strong arguments in favor of early tympanoplasty.^{4,5} This controversy is certainly enhanced by the variable success rates mentioned in the literature, due to large differences in selection criteria, definition of success, and length of follow-up.

Allograft (or homograft) tympanoplasty was first introduced by Jean Marquet⁶ in 1966. He advocated the use of allograft tympanic membrane and ossicles in order to obtain an optimal anatomic and functional reconstruction of the middle ear in chronic middle ear disease (Fig 1). The present authors were trained by him, and as did J. Marquet, they also routinely transplant tympanic membranes in children.

This paper reports on a retrospective analysis of the anatomic and functional results of type 1 tympanoplasty in the childhood population. It does not address the alleged risk of transfer of infectious diseases, namely, Creutzfeldt-Jakob disease (CJD) and human immunodeficiency virus (HIV). Trans-

mission of CJD has never been reported after transplantation of other than brain tissue or cadaveric dura mater. It is reported in 10 cases after the implantation of dura mater grafts.⁷ In addition, the incidence of CJD is extremely low (1 per 1 million), and stringent criteria for donor selection should exclude donors who are at risk for CJD. No cases of transmission of HIV have been reported with nonvital allograft material. Preservation with formaldehyde is accepted to eliminate HIV.⁸

MATERIALS AND METHODS

For the present retrospective study, the consecutive files (November 1982 to November 1993) of children who underwent tympanoplasty type 1 under the age of 16 were retrieved and numbered 78. Only patients with a tympanic membrane perforation with-

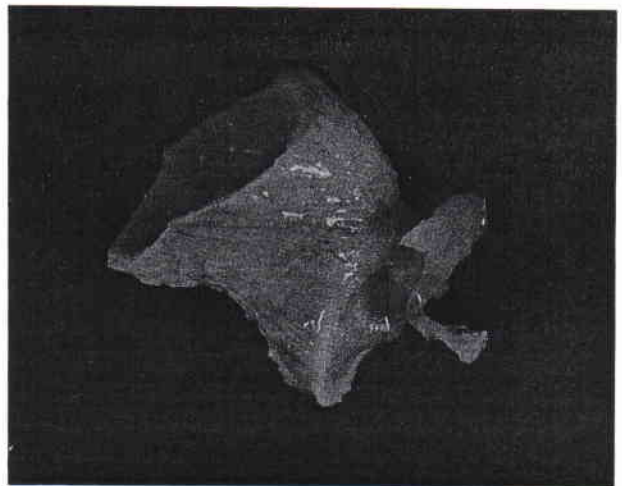


Fig 1. Tympano-ossicular allograft.

From the Department of Otorhinolaryngology, St Augustinus Hospital, University of Antwerp, Antwerp-Wilrijk, Belgium.

CORRESPONDENCE — Paul J. Govaerts, MD, MS, St Augustinus Hospital, Oosterveldlaan 24, 2610 Antwerp-Wilrijk, Belgium.

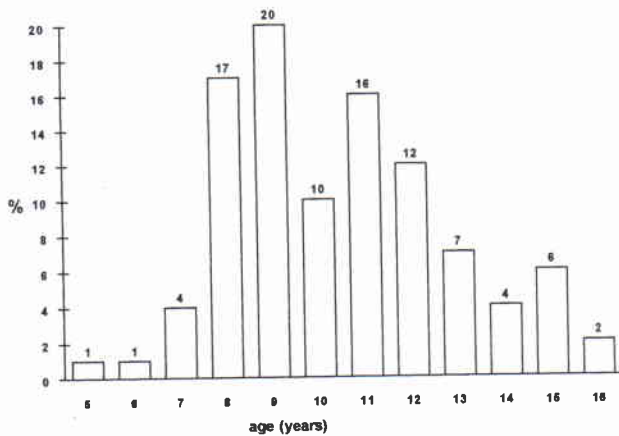


Fig 2. Age distribution at time of surgery.

out cholesteatoma and with a normal ossicular chain were selected. Revision surgery was excluded, as well as retraction pockets and cases operated on with the underlay technique. Of these 78 operations, 8 were excluded because they were considered statistically dependent cases because the other ear had already been enrolled in the present study. In such a case, a random choice was made as to which ear to include. Hence, 70 ears remained for the present statistical study.

Surgery was performed under general anesthesia with hypotension. The technique of allograft tympanoplasty according to Marquet⁹ was used. Briefly, a retroauricular incision and dissection of the skin and of the external auditory canal is performed, followed by a total myringectomy. An allograft tympanic membrane is fitted in the bony annulus, and the skin of the external auditory canal is repositioned over the cuff of the allograft. An external ear canal packing with an antibiotic ointment is left in place for 1 week.

Allograft tympanic membranes were harvested and prepared in the temporal bone bank of St Augustinus Hospital, according to the standards prescribed by Belgian law (Belgisch Staatsblad, 13/6/1986). The grafts were preserved by being left in formaldehyde for at least 2 weeks followed by Cialit (Hoechst Pharmaceuticals) for a minimum of 3 weeks.

Nineteen variables were studied, namely, age, sex, side, surgeon, cause and site of the perforation, state of the mucosa, state of the contralateral ear, and history of mastoidectomy and adenoidectomy, together with three postoperative evaluations (at 3 and 12 months and the latest evaluation available) in terms of state of the graft, presence of perforation, and state of the outer ear canal. Whenever available, four full audiometries (bone and air conduction) were analyzed: the preoperative audiogram, the audiograms at 3 and 12 months postoperatively, and the

TABLE 1. SITE AND SIZE OF PERFORATION

Site and Size of Perforation	% of Cases
Small anterior	6
Small posterior	15
Large anterior	10
Large posterior	24
Large inferior	14
Subtotal	31

Small—restricted to one quadrant, large—restricted to two neighboring quadrants, subtotal—occupying more than two quadrants.

latest audiogram. Audiometry was performed in a soundproof room with an audiometer calibrated according to ISO (International Standards Organization) standards. A lack of response to air-conducted sound was coded as 120 dB, and to bone-conducted sound as 80 dB. Missing values were coded as such. Descriptive statistics were performed on all variables. Counts, percentages, and histograms were used to describe nominal data.

Hence, audiometric results (often expressed as the Fletcher index, ie, the mean of hearing levels at 500, 1,000, and 2,000 Hz) were described by means of nonparametric statistics. Analytic statistics were performed to study the interdependence of all variables and the dependence of the audiometric results on the different variables. The null hypothesis of independence was tested for each two separate variables. We used *t*-tests for independent variables, χ^2 tests, and ANOVA tests (analysis of variance). All tests were carried out two-tailed.

A Kruskal-Wallis analysis of variance was used to test the dependence of the audiometric results on the different variables. A Pearson correlation analysis was used to test the dependence of the audiometric results on age. All tests were carried out two-tailed. A global level of significance for the whole present study of 5% was set forward. In consequence, according to the Bonferroni principle, a much more stringent significance level was set for each individual test and only *p* values of 0.1% were considered significant. Taking into account an alpha error of 0.001 and a beta error of 0.20, the present study design was able to demonstrate audiometric differences of approximately 10 dB. All statistics were performed by a computer running CSS/pc software (release 2.1; Statsoft Inc).

RESULTS

The male-to-female ratio was 59:41. The right-left distribution was 53:47. The mean age was 10.3 years (range 5 to 16 years). The mean follow-up was 40 months (range 1.6 to 132 months). The age distribution at the time of surgery is shown in Fig 2. The site and size of the perforation are shown in Table 1. The

TABLE 2. ANATOMIC RESULTS IN TERMS OF STATE OF GRAFT DURING FOLLOW-UP

State of Graft	% of Cases		
	3 Months	12 Months	Latest Evaluation
Normal graft	88	82	74.5
Retraction	1.5	1.5	1.5
Lateralization without FRs	4.5	7.5	3
Lateralization with FRs			6
Edema of graft	0	0	1.5
Granulation on graft	3	3	1.5
Perforation	3	6	12

Lateralization — (partial) loss of contact between malleus handle and graft, FRs — functional repercussions, edema — thickening of graft with incomplete epithelialization.

perforation was a sequela of chronic otitis media in 87%, of the presence of a ventilation tube in 10%, and of trauma in 3%. The state of the contralateral ear was normal in 52% of cases. In 14% the contralateral ear showed active aeration problems such as retraction, atelectasis, or effusion. In 23% a contralateral perforation was present, and in 11% the contralateral ear was normal after previous surgery that had been performed for chronic otitis media. None of the contralateral ears showed cholesteatoma. The state of the middle ear mucosa at the time of surgery was normal in 86%, discharging in 2%, and edematous in 12%. In 10% of cases surgery was combined with mastoidectomy. Information about adenoidectomy was available in only 31 cases, in the majority of which (94%) adenoidectomy had been performed earlier.

The anatomic results in terms of state of the graft and reperforation of the graft are presented in Table 2 and Fig 3. The outer ear canal showed stenosis at 3 months in 1 case, which was treated with good results, and edema in another case. The later evaluations showed no outer ear canal abnormalities.

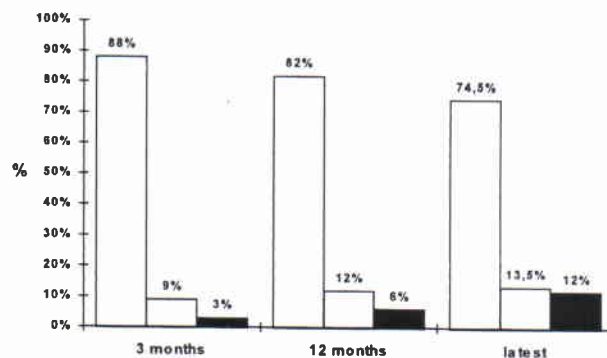


Fig 3. Anatomic results in terms of state of graft. White — normal, shaded — intact with complication, black — perforation. (Complications are specified in Table 2.)

The audiometric results at 3 months and 12 months are presented in Fig 4. The median preoperative bone and air conduction thresholds and the postoperative air conduction threshold are presented over all frequencies. The median hearing gain is 10 dB at 3 and 12 months and at the latest evaluation.

No significant correlation between the different variables was found, except for the contralateral ear, which in older children presented more often a history of previous surgery for chronic otitis media than in younger children ($p = .005$).

DISCUSSION

The success rate of type 1 tympanoplasty in children varies among the different authors. This is due to differences in selection criteria, definition of success, and length of follow-up. There is no study in the literature using exactly the same inclusion criteria for evaluation of success of type 1 tympanoplasty in children. All authors on this subject have studied a heterogeneous group including dry perforations, ossicular chain damage, revision surgery, and bilaterally operated cases.

When defining anatomic success of type 1 tym-

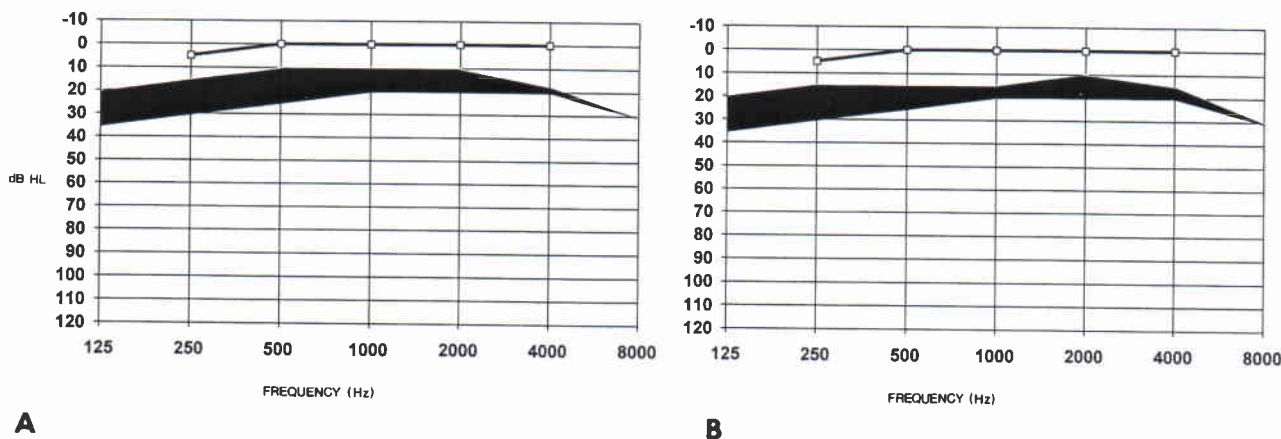


Fig 4. Audiometric data. Preoperative bone conduction thresholds (black line) and preoperative and postoperative air conduction thresholds (lower and upper borders of black area). A) After 3 months. B) After 12 months.

panoplasty as a nonperforated graft, our short-term success rate is 97% and long-term success rate 88%. The success rates of other papers vary from 35%² to 93%¹⁰ because of different definitions of success. Bluestone et al² considered tympanoplasty to have failed when negative middle ear pressure or serous effusion returned postoperatively. Tos¹¹ used the audiologic outcome to report surgical success in a population with heterogeneous disorders. It is intuitively logical that surgical outcome will vary with the severity of disease. Papers that can be well compared with the present study in terms of inclusion criteria and study design report success rates of 66% (follow-up 25.2 months),¹² 73% (follow-up 23.4 months),¹³ 78% (follow-up 72 months),¹⁴ and 81% (follow-up 19 months).¹⁵ In all these papers, temporalis fascia was used as graft material in underlay. Compared with these papers, we report the highest success rate, with a long-term mean follow-up of 40 months. It is remarkable that papers including patients with more advanced middle ear disease, such as ossicular chain damage, report comparable success rates.¹⁶⁻¹⁹

A possible cause of failure after tympanoplasty is the development of secretory otitis media as a result of insufficient aeration of the middle ear. There is no reliable method for preoperative evaluation of the middle ear aeration, and therefore, the risk of postoperative secretory otitis media is hardly predictable. The status of the contralateral ear may be an indication,^{12,20} although several authors reported that this factor had no predictive value for success of tympanoplasty.^{15,18,21,22} In the present study no correlation was found between the status of the contralateral ear and surgical outcome, but the relatively small sample size of the subgroups renders statistical analysis inconclusive.

In the present study only 1 case presented with a perforation 4 years postoperatively after an episode of acute otitis media with purulent otorrhea. Four cases presented with a perforation after an episode of granulation on the graft, treated with local antibiotics. In 2 of these cases, granulation appeared 3 years postoperatively. In 1 case the perforation was preceded by stenosis of the outer ear canal, which was treated with good results.

Information on antibiotic administration preoperatively and postoperatively was not sufficiently available to include it as a variable in this study. Antibiotics were not given systematically. A possible effect of antibiotics on the surgical outcome has never been proven.

Previous studies have noted late graft failures even

after many years.^{14,21,23,24} The pathogenesis of these late failures can be related to middle ear aeration deficiency, which was in many cases the original cause of the perforation. An episode of acute otitis media can result in perforation of the graft, even after a long time. Clearance deficiency of the external ear followed by granulation tissue, with subsequent perforation, unrelated to the aeration capacity of the middle ear, could be considered another possible cause of late postoperative perforations. Therefore, strict short-term follow-up for local control of the graft and outer ear canal during the first 6 months is very important. It is our policy to forbid swimming for 6 months and flying for 2 months. Annual control until the age of 16 is recommended.

Besides perforation, an allograft tympanic membrane can show other anatomic problems (Table 2). A retracted graft (no retraction pocket) was found in 1.5% on both short-term and long-term evaluation. MacDonald et al¹⁶ report 5 of 29 cases to show postoperatively retracted grafts after fascia myringoplasty.

An alleged complication of this surgical technique is lateral displacement of the graft. We define lateral displacement as the otoscopic situation of partial or complete loss of contact between the tympanic membrane and the malleus handle. This situation was found in 4.5% of cases at the short-term evaluation. It is evident that anatomic and functional results cannot be considered separately. Therefore, at the long-term evaluation a distinction was made between lateral displacement with and without functional repercussion. As presented in Table 2, 4 of 6 cases (6%) showed lateral displacement with functional repercussion (hearing unchanged or diminished). Of these 4 cases, only 1 showed a complete loss of contact between the graft and malleus, and 3 cases a partial loss of contact with the malleus handle. Two cases (3%) developed partial lateral displacement with normal hearing improvement as seen in the cases with a normal graft. These 2 cases had neither a functional nor a hygienic problem and the displacement cannot be called a complication.

In the literature, controversy exists about the timing of tympanoplasty in children with a dry perforation. The present study shows that tympanoplasty was performed from the age of 5 years. No correlation was found between age and surgical outcome. Of course, there was a tendency to delay surgery in cases of recurrent upper respiratory tract infections, adenoid hypertrophy, or nasal allergy, which were treated first. This tendency is nicely expressed by the 86% dry ears at the time of surgery. Still, no correlation was found between status of the middle ear mucosa

and success rate. Some authors do not recommend tympanoplasty under the age of 10 years.^{2,12,16,25} Shih et al²⁶ and Berger et al²¹ reported more failures under the age of 10 years. Sheehy and Anderson²⁷ do not recommend elective surgery before 7 years and Raine and Singh²³ suggest waiting to 12 years. Several authors state that age is of no significant influence.^{15,17-20,22,28} Smyth and Hassard⁴ recommend myringoplasty as early as possible. According to our results there is no need to delay surgery until a "magic age." If a child presents with favorable conditions as mentioned before, surgery can be performed as soon as possible. The cause of the perforation showed no correlation with graft take. There was a tendency for the large perforations to be less successful, but the correlation was not significant. Possibly, the size of the perforation is a measure of the stage of middle ear disease. More advanced middle ear disease could have a higher failure rate after tympanoplasty. In contrast with the fascia temporalis underlay technique, the site and size of the perforation are of no importance in the technique of allograft type I tympanoplasty, which is identical in all cases. Hearing function is hardly ever the main indication for allograft tympanoplasty type 1 in dry perforations, yet it is a factor to be evaluated.

None of the ears presented with a postoperative sensorineural hearing loss or facial nerve palsy. The

median preoperative air conduction threshold (Fletcher index) was 22 dB. No statistical significance was found between the named variables and the audiologic outcome. The median hearing gain at 3 and 12 months and at the latest evaluation was 10 dB. Of the four comparable papers mentioned earlier, only two report useful audiometric data.^{14,15} Kessler et al¹⁵ report that 90% of cases have a postoperative air-bone gap of 20 dB or less. No preoperative data were mentioned. Blanshard et al¹⁴ report a closure of the air-bone gap to within 10 dB, averaged over the frequency range 250 Hz to 4 kHz, in 18% at the long-term follow-up (6 years). Other papers are hardly comparable on their audiometric results, because they include ossicular chain damage and revision surgery. These factors have too much impact on audiometric data for comparison with the population of the present study.

In conclusion, we state that allograft type 1 tympanoplasty is anatomically and functionally successful in this selected group of children, regardless of age. The functional success of allograft tympanoplasty is at least comparable to that of fascia tympanoplasty (according to literature reports), whereas the take rate appears to be higher. There is no obvious influence of the different variables postulated to affect the surgical outcome of type 1 tympanoplasty. This might be due to the small sample size of the subgroups.

REFERENCES

1. Wullstein HL. Operationen am Mittelohr mit Hilfe des freien Spaltlappentransplantaten. *Arch Ohren Nasen Kehlkopfheilkd* 1952;161:422-35.
2. Bluestone C, Cantekin E, Douglas G. Eustachian tube function related to the results of tympanoplasty in children. *Laryngoscope* 1979;89:450-8.
3. Proctor B. Tympanoplasty in children: some considerations of the pathology encountered. *Mich Med* 1975;74:375-7.
4. Smyth G, Hassard T. Tympanoplasty in children. *Am J Otol* 1980;1:199-205.
5. Armstrong H. Tympanoplasty in children. *Laryngoscope* 1965;75:1062-9.
6. Marquet J. Reconstructive microsurgery of the eardrum by means of a tympanic membrane homograft. *Acta Otolaryngol (Stockh)* 1966;62:459-67.
7. Martinez-Lage J, Poza M, Sola J, et al. Accidental transmission of Creutzfeldt-Jakob disease by dural cadaveric grafts. *J Neurol Neurosurg Psychiatry* 1994;57:1091-4.
8. Glasscock ME III, Jackson CG, Knox GW. Can acquired immunodeficiency syndrome and Creutzfeldt-Jakob disease be transmitted via otologic homografts? *Arch Otolaryngol Head Neck Surg* 1988;114:1252-5.
9. Marquet J. Allografts and tympanoplasty and other forms of middle ear surgery. In: Ballantyne JC, Morrison A, eds. *Operative surgery*. London, England: Butterworths, 1986:102-26.
10. Friedberg J, Gillis T. Tympanoplasty in childhood. *J Otolaryngol* 1980;9:165-8.
11. Tos M. Tympanoplasty and age. *Arch Otolaryngol* 1972;96:493-8.
12. Buchwach KA, Birck HG. Serous otitis media and type 1 tympanoplasties in children. A retrospective study. *Ann Otol Rhinol Laryngol [Suppl]* 1980;89(suppl 68):324-5.
13. Koch W, Friedman E, McGill T, Healy G. Tympanoplasty in children. *Arch Otolaryngol Head Neck Surg* 1990;116:35-40.
14. Blanshard J, Robson A, Smith I, Maw A. A long term view of myringoplasty in children. *J Laryngol Otol* 1990;104:758-62.
15. Kessler A, Potsic W, Marsh R. Type 1 tympanoplasty in children. *Arch Otolaryngol Head Neck Surg* 1994;120:487-90.
16. MacDonald R, Lusk R, Muntz H. Fasciaform myringoplasty in children. *Arch Otolaryngol Head Neck Surg* 1994;120:138-43.
17. Lau T, Tos M. Tympanoplasty in children: an analysis of late results. *Am J Otol* 1986;7:55-9.
18. Ophir D, Porat W, Marshak G. Myringoplasty in the pediatric population. *Arch Otolaryngol Head Neck Surg* 1987;113:1288-90.
19. Vartiainen E. Results of surgical treatment for chronic noncholesteatomatous otitis media in the pediatric population. *Int J Pediatr Otorhinolaryngol* 1992;24:209-16.
20. Adkins W, White B. Type 1 tympanoplasty: influencing factors. *Laryngoscope* 1984;94:916-8.
21. Berger G, Shapira A, Marshak G. Myringoplasty in chil-

dren. *J Otolaryngol* 1983;12:228-30.

22. Claes J, van de Heyning P, Creten W, et al. Allograft tympanoplasty: predictive value of preoperative status. *Laryngoscope* 1990;100:1313-8.

23. Raine C, Singh S. Tympanoplasty in children. A review of 114 cases. *J Laryngol Otol* 1983;97:217-21.

24. Sadé J, Berco E, Brown M, Weinberg J, Avraham S. Myringoplasty: short and long-term results in a training program. *J Laryngol Otol* 1981;95:653-65.

25. Dawes J. Myringoplasty. *J Laryngol Otol* 1972;86:141-6.

26. Shih L, Tar T, Crabtree J. Myringoplasty in children. *Otolaryngol Head Neck Surg* 1991;105:74-7.

27. Sheehy JL, Anderson RG. Myringoplasty. A review of 472 cases. *Ann Otol Rhinol Laryngol* 1980;89:331-4.

28. Prescott C, Robartes W. Tympanoplasty surgery at the Red Cross War Memorial Children's Hospital 1986-1988. *Int J Pediatr Otorhinolaryngol* 1991;21:227-34.